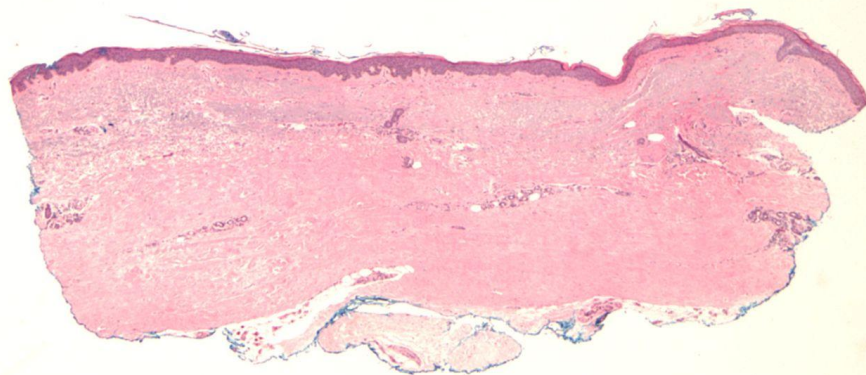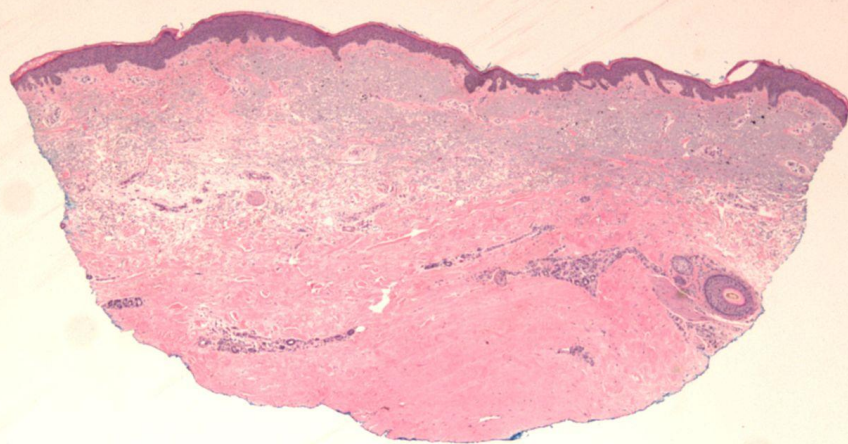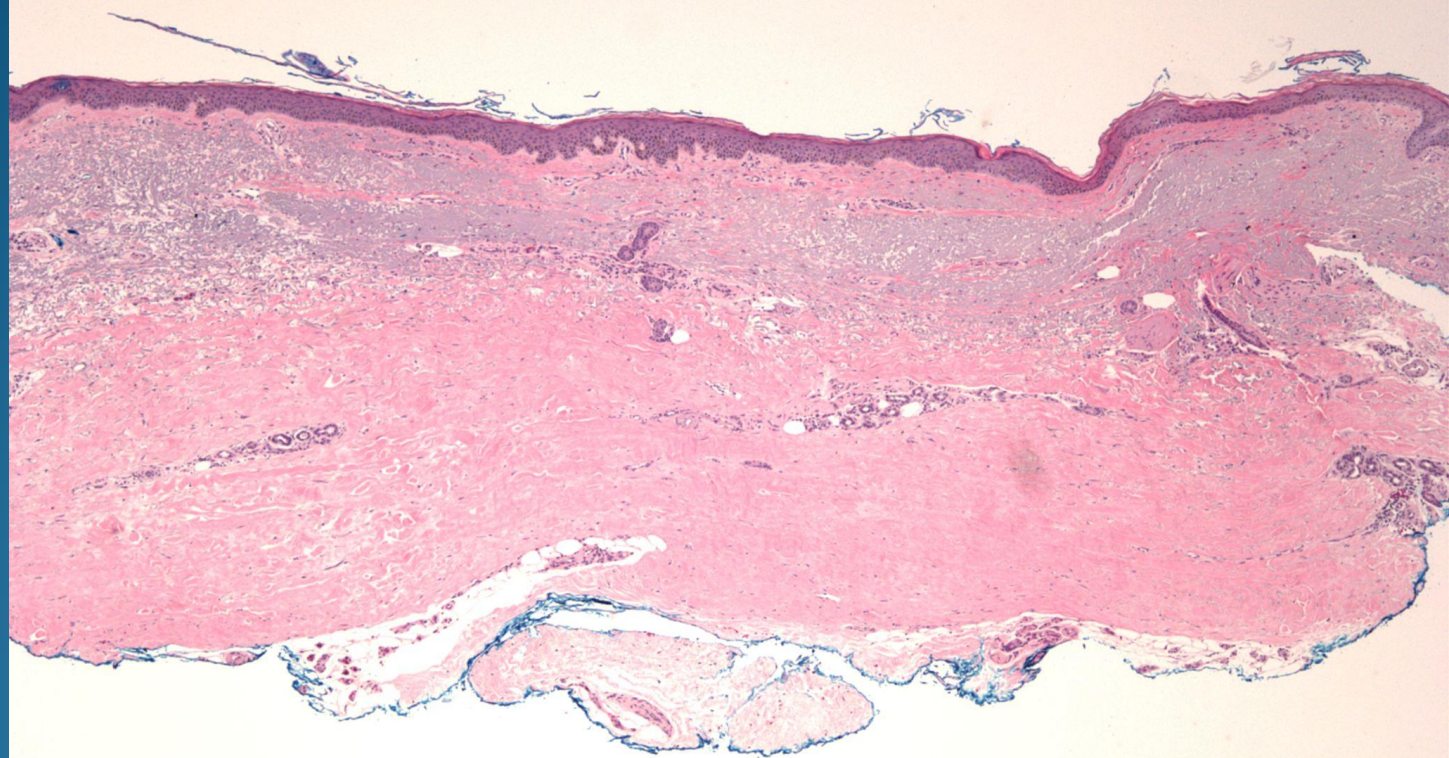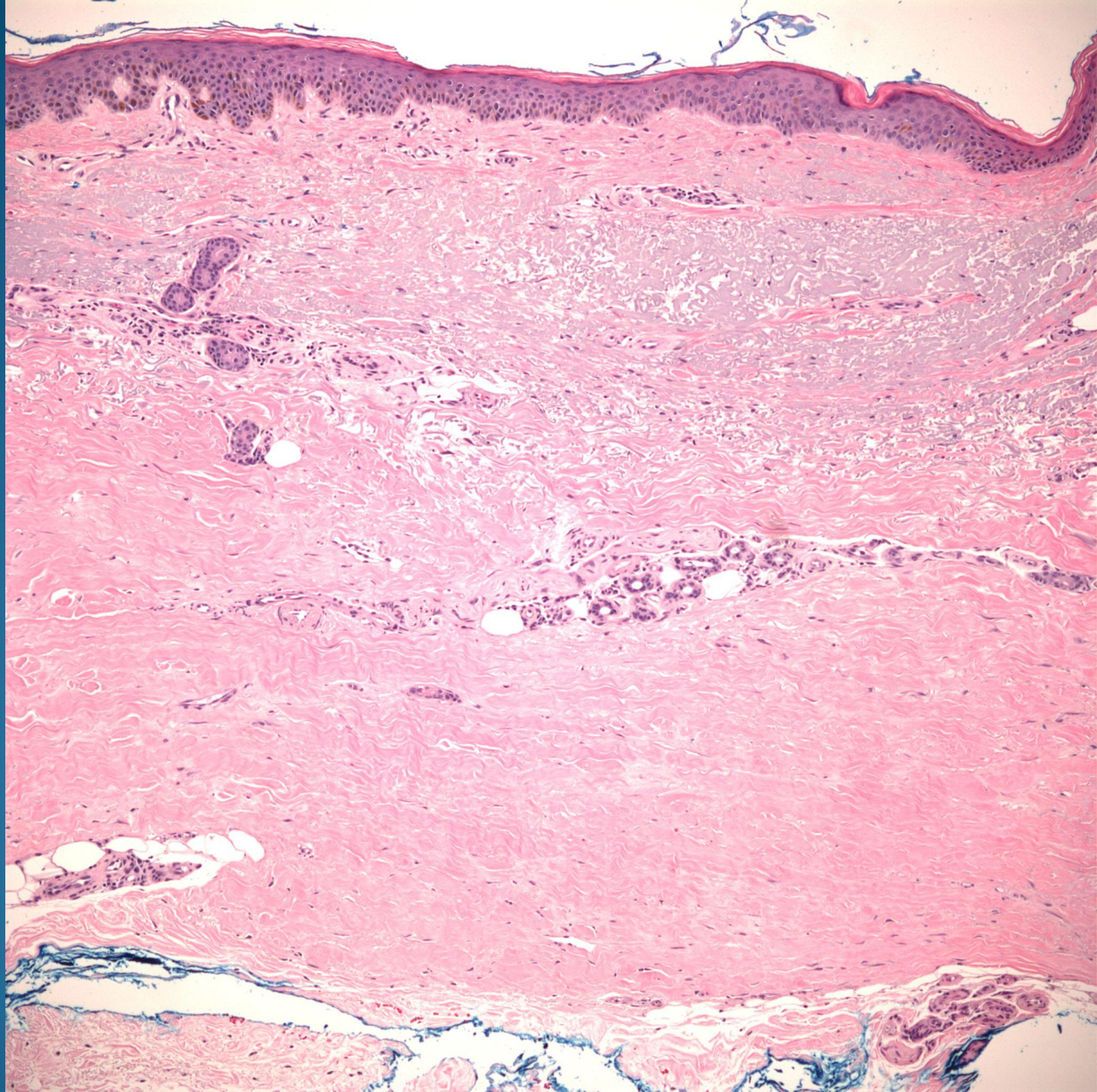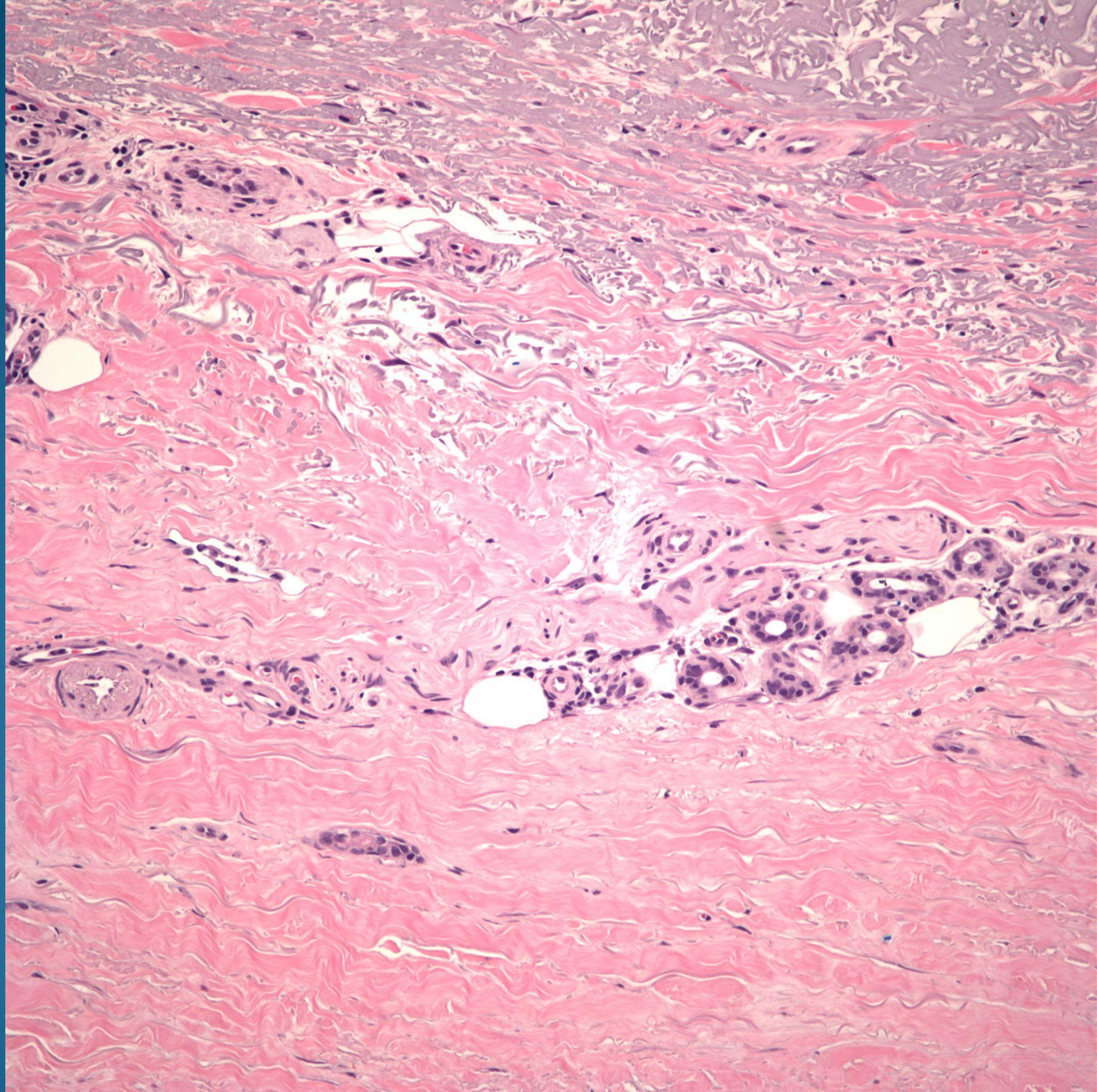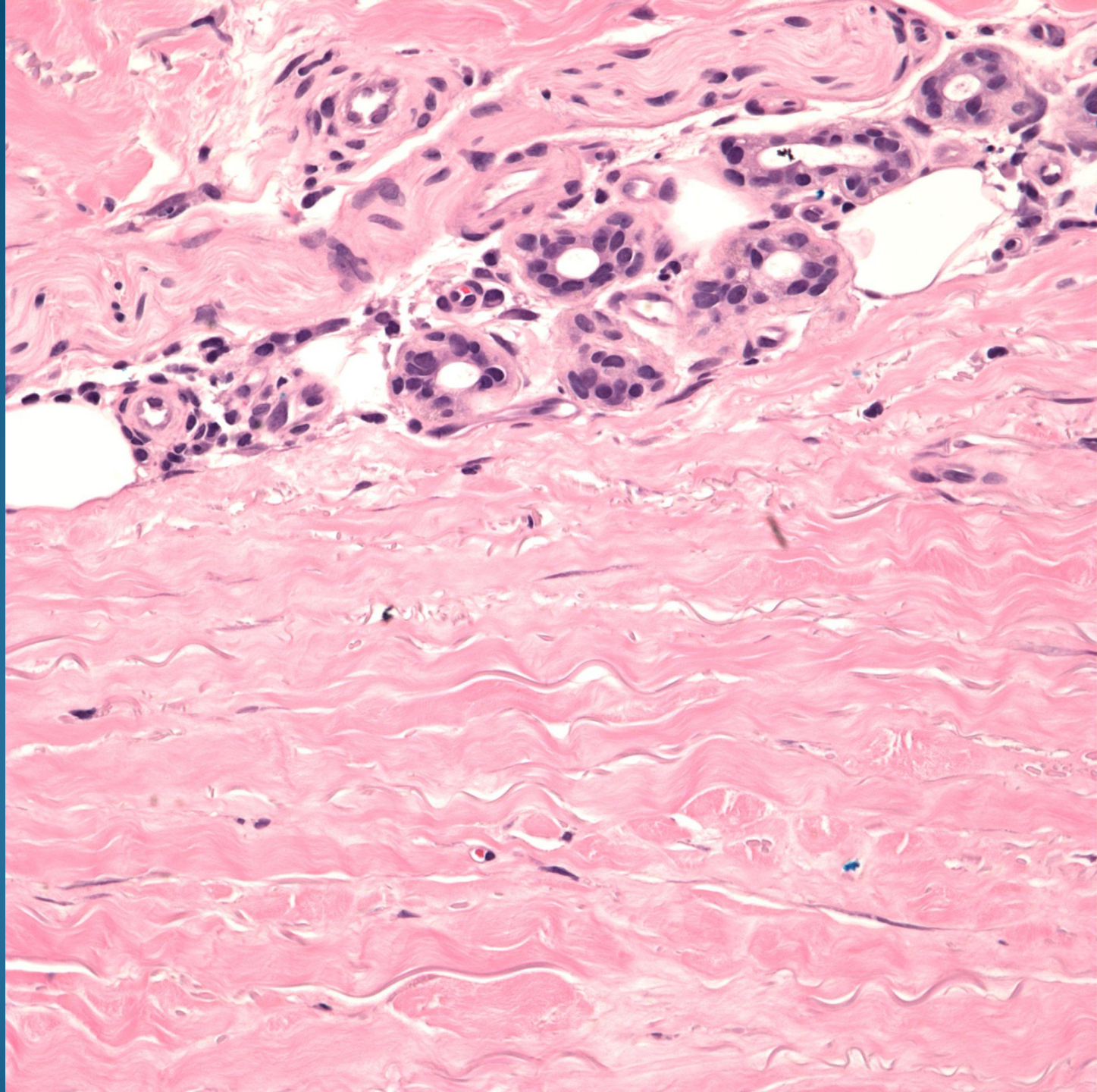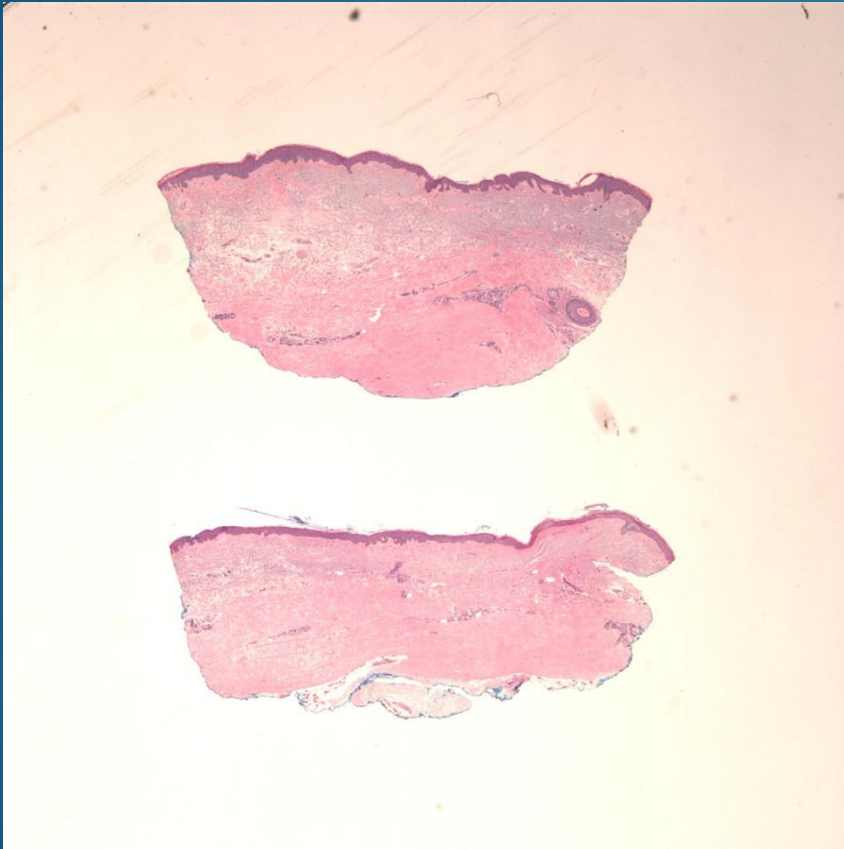


# Scleroderma

# Pearls



- “Square” biopsy sign
- Histologically identical to morphea, distinguish by clinical presentation
- Diffuse dermal sclerosis, predominately deeper dermis
- May have residual perivascular/  
periadnexal chronic inflammatory cell infiltrate